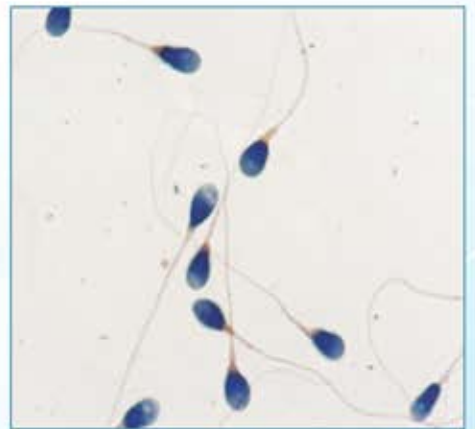
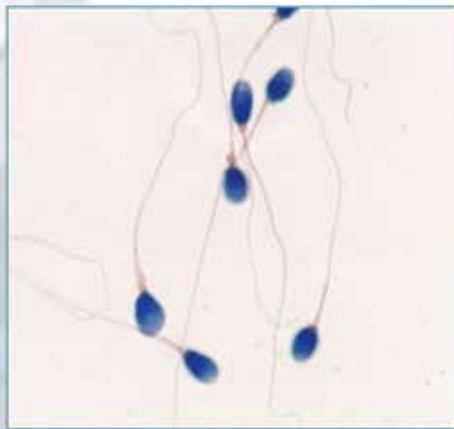
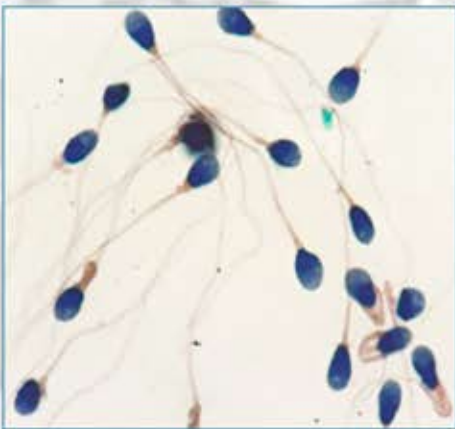
**Cryo**  **Lab**  
INTERNATIONAL



# Easy Morpho Kit



Easy Morpho

## Easy Morpho Slides ( Prestained Slides for Sperm Morphology assessment)

Spermatozoon is an intricate motile cell with a well defined head, neck and tail. The shape of the normal sperm is a reflection of proper spermatogenesis in the testicles. Recent studies have highlighted the importance of sperm morphology assessment. It suggests that there is a definite association between poor sperm morphology and decreased pregnancy rates. Thus Sperm morphology evaluation is considered to be the best predictive factor in natural conception, IUI and an IVF procedure. Sperm morphology assessment using Easy Morpho slides is reliable, simple and inexpensive and can provide essential information similar to the results obtained from complicated staining protocols.

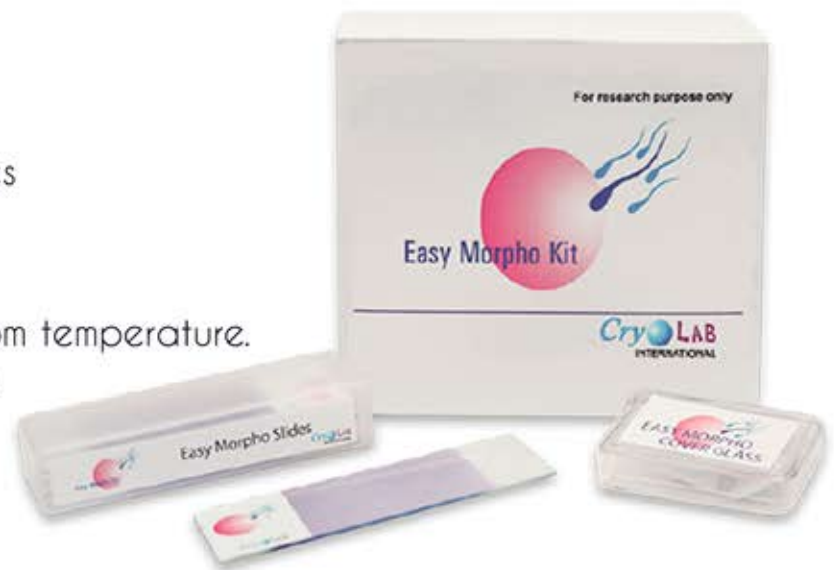### Package Contents

The package contains:

- 10 Prestained ready-to-use slides

### Specimen Preparation

1. Wear safety rubber gloves
2. Allow the semen to liquefy at room temperature.
3. Immediately prior to application, mix the specimen thoroughly.



### Procedure

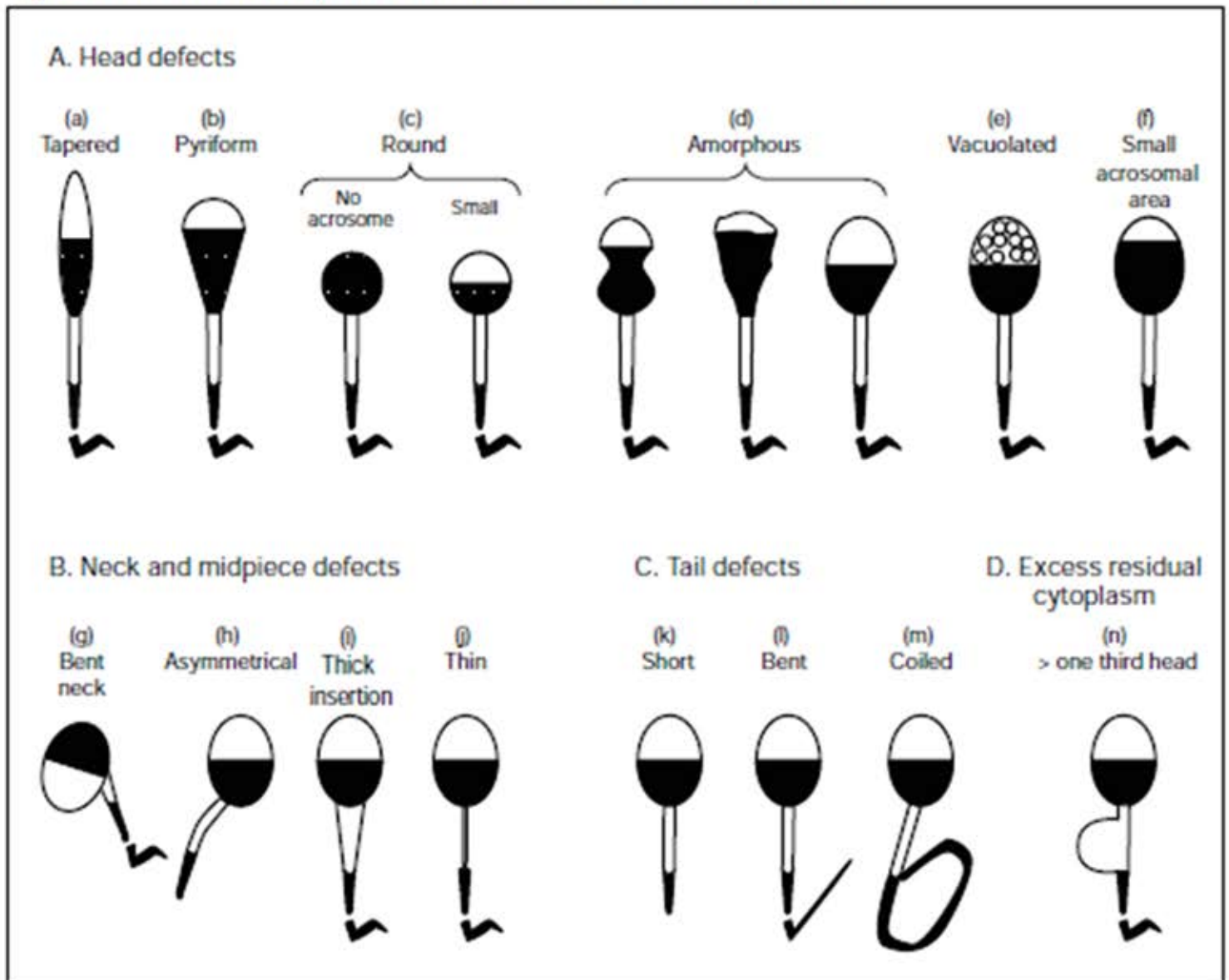
1. Pipette 10 $\mu$ l of the well-mixed, liquefied semen sample directly to the center of the stained portion of the labeled slide.
2. Place the cover glass on the specimen immediately. Press the cover glass to create a thin smear.
3. Allow the prepared slide to stand at least 45 minutes at room temperature before evaluating.
5. Examine the slides under oil immersion, using an 100x objective.
6. Count at least 200 spermatozoa. Tally the number of normal and abnormal spermatozoa with the aid of a laboratory counter. Classify them using WHO 'Strict Criteria'.
8. Note the presence of other cells. List and classify them as; immature germinal cells, white blood cells, or epithelial cells.

**Lower reference limit** The lower reference limit for normal forms is 4% (5th centile, 95% CI 3.0–4.0).

**Reference:** World Health Organization. WHO Laboratory Manual for the Examination and Processing of Human Semen. 5th ed. Geneva: World Health Organization; 2010

**Storage:** The kit should be stored in a cool, dark place. Keep the box tightly closed after use.

Fig. 2.13 Schematic drawings of some abnormal forms of human spermatozoa

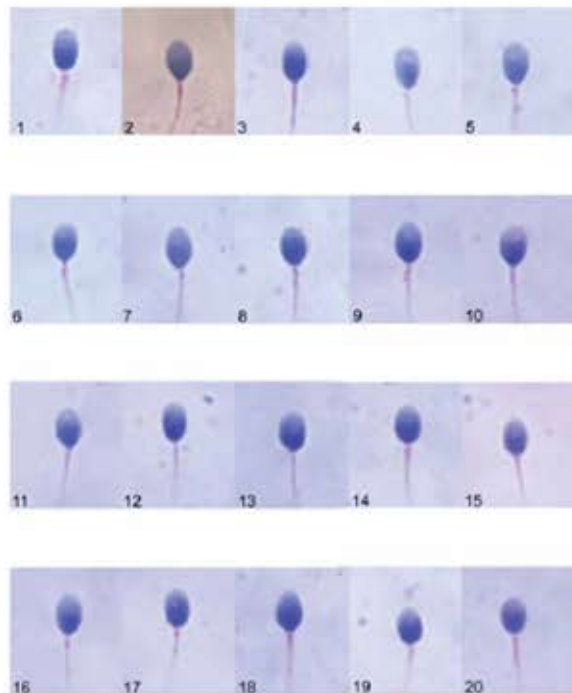


Adapted from Kruger et al., 1993 and reproduced by permission of MQ Medical.

Table 2.6 Explanations used in commentaries to Plates 1–14

<40% acr	less than 40% of the sperm head is occupied by the acrosome
>70% acr	more than 70% of the sperm head is occupied by the acrosome
>one third	abnormal cytoplasm (more than one third of head size) (ERC)
<one third	normal cytoplasm (less than one third of head size) (CD)
abnormal	self-explanatory
amorphous	head shape (see Fig. 2.13d)
bacilli	bacteria
bent	unnaturally sharp angulation (see Figs 2.13g and j)
coiled	self-explanatory
CD	cytoplasmic droplet
cytoplasm	either excess residual cytoplasm or cytoplasmic droplet, depending on size
degenerating leukocyte	self-explanatory
degenerating spermatid	self-explanatory
defect	self-explanatory
double	self-explanatory
epithelial cell	from male duct system
ERC	excess residual cytoplasm (see Fig. 2.13n)
flat	base of sperm head not oval
focus	out of focus (not assessed)
if PP OK	not all the principal piece is seen in the micrograph (but if it were normal, the spermatozoon would be considered normal)
insert	the site of insertion of the tail is to one side of the long axis of the head
irreg	irregular in outline
looped	tail bent back on itself
macrophage	phagocytic leukocyte
monocyte	agranular leukocyte
spermatid	immature germ cell
no acro	acrosome absent
normal	resembling those found in endocervical mucus
not assessed	because of overlap or poor focus
overlapping	heads obscured by tail
PA vac	vacuole in the post-acrosomal region
pinhead	not a spermatozoon; no chromatin present
polymorph	polymorphonuclear leukocyte
pyriform	head shape (see Fig. 2.13b)
round	head shape (see Fig. 2.13c)
side view	spermatozoon seen edge on
small	head size
spermatid	immature germ cell
spermatocyte	immature germ cell
tapered	head shape (see Fig. 2.13a)
thick	self-explanatory
too long	self-explanatory
vac	vacuole
>2 vac	more than two vacuoles

10 microns Plate 1

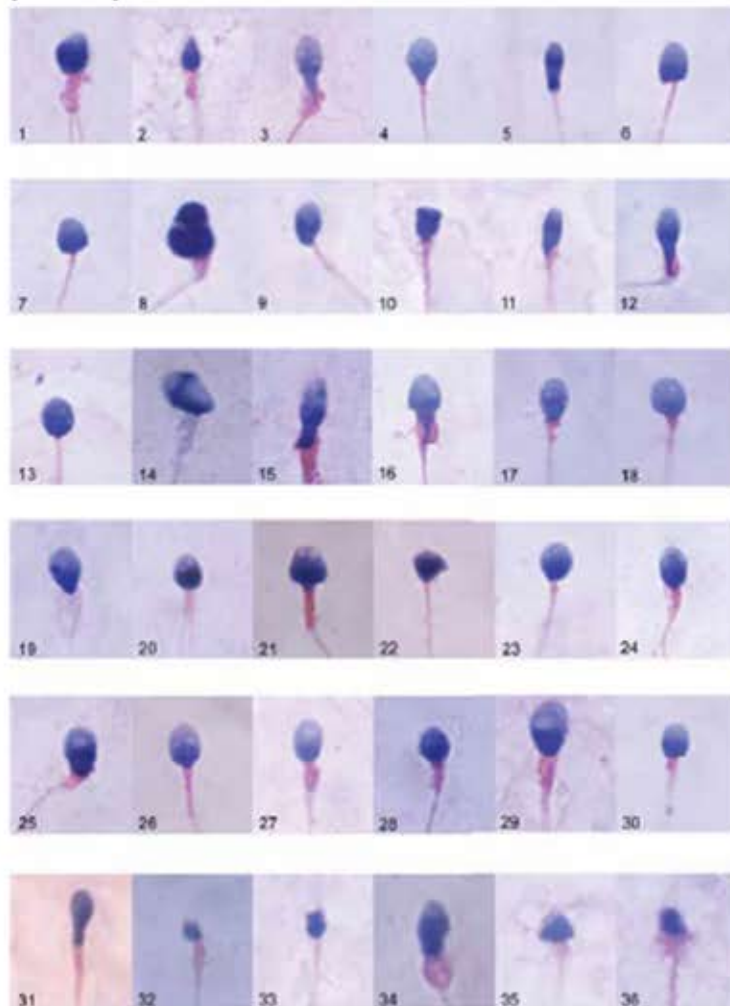


Micrographs courtesy of C. Braut

Morphology assessment of spermatozoa in Plate 1

Sperm	Head shape	Other head comments	Midpiece comments	Principal piece comments	Overall sperm classification	Comments
1	normal		normal		normal	if PP OK
2	normal		normal		normal	if PP OK
3	normal		normal		normal	if PP OK
4	normal		normal		normal	if PP OK
5	normal		normal		normal	if PP OK
6	normal		normal		normal	if PP OK
7	normal		normal		normal	if PP OK
8	normal		normal		normal	if PP OK
9	normal		normal		normal	if PP OK
10	normal		normal		normal	if PP OK
11	normal		normal		normal	if PP OK
12	normal		normal		normal	if PP OK
13	normal		normal		normal	if PP OK
14	normal		normal		normal	if PP OK
15	normal		normal		normal	if PP OK
16	normal		normal		normal	if PP OK
17	normal		normal		normal	if PP OK
18	normal		normal		normal	if PP OK
19	normal		normal		normal	if PP OK
20	normal		normal		normal	if PP OK

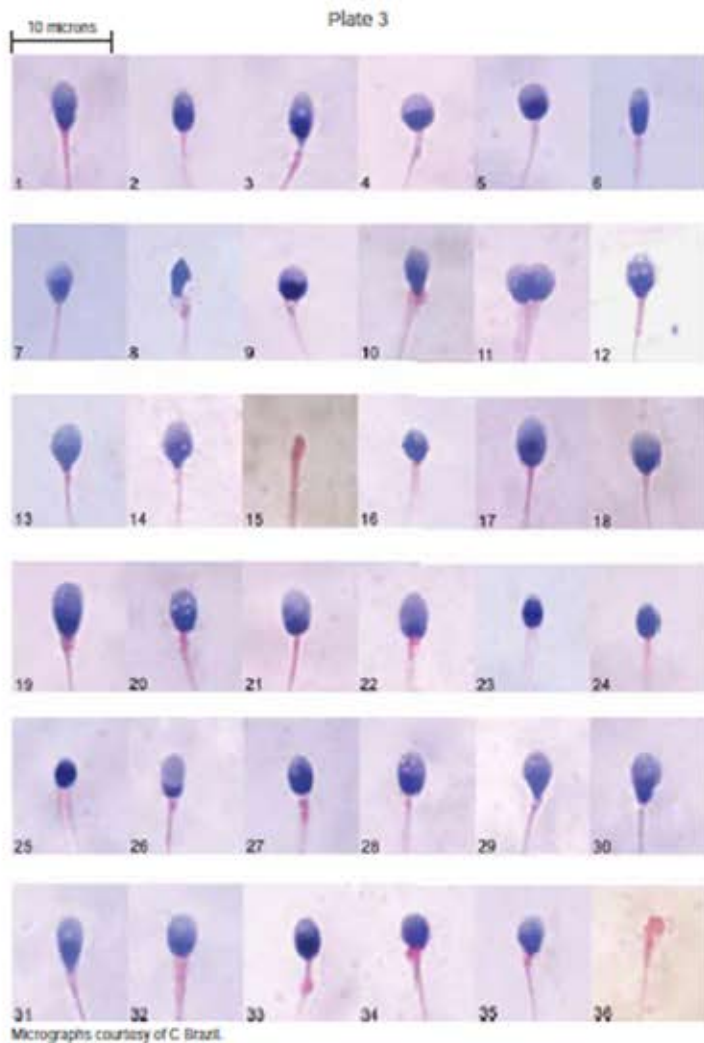
10 microns Plate 2



Micrographs courtesy of C. Braut


Morphology assessment of spermatozoa in Plate 2

Sperm	Head shape	Other head comments	Midpiece comments	Principal piece comments	Overall sperm classification	Comments
1	abnormal		thick	double	abnormal	
2	abnormal		irreg		abnormal	side view
3	abnormal	pyriform	bent, irreg, ERC		abnormal	>one third
4	abnormal				abnormal	
5	abnormal	pyriform			abnormal	
6	abnormal				abnormal	
7	abnormal				abnormal	
8	abnormal		thick		abnormal	
9	abnormal		insert		abnormal	
10	abnormal				abnormal	
11	abnormal				abnormal	
12	abnormal	pyriform		bent	abnormal	
13	abnormal	>2 vac, PA vac			abnormal	
14	abnormal		thick		abnormal	
15	abnormal	pyriform	thick, ERC		abnormal	>one third
16	abnormal	pyriform	ERC		abnormal	>one third
17	normal	PA vac			abnormal	
18	abnormal		thick, insert		abnormal	
19	abnormal		abnormal		abnormal	
20	abnormal		thick		abnormal	
21	abnormal		thick		abnormal	
22	abnormal				abnormal	
23	abnormal				abnormal	
24	normal	>2 vac	thick		abnormal	
25	abnormal		thick, bent		abnormal	
26	abnormal		thick		abnormal	
27	abnormal	>70% acr	thick		abnormal	
28	abnormal		thick		abnormal	
29	abnormal		thick		abnormal	
30	abnormal		thick		abnormal	
31	abnormal	pyriform	thick		abnormal	
32	abnormal	small	thick		abnormal	
33	abnormal	small	thick		abnormal	
34	abnormal		ERC		abnormal	>one third
35	abnormal		thick		abnormal	
36	abnormal		thick		abnormal	



Morphology assessment of spermatozoa in Plate 3

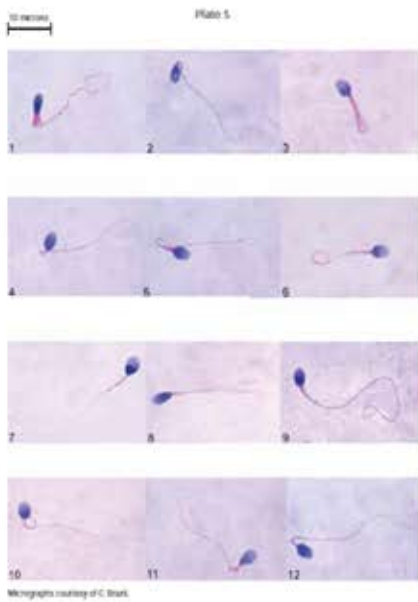
Sperm	Head shape	Other head comments	Midpiece comments	Principal piece comments	Overall sperm classification	Comments
1	abnormal	tapered	thick		abnormal	
2	abnormal				abnormal	
3	abnormal		irreg		abnormal	
4	abnormal	round			abnormal	
5	abnormal	round			abnormal	
6	abnormal	tapered			abnormal	
7	abnormal	tapered			abnormal	
8	abnormal	amorphous	thick		abnormal	
9	abnormal	round	thick		abnormal	
10	abnormal	tapered	irreg, thick		abnormal	
11	—				—	two coils
12	abnormal	>2 vac, PA vac			abnormal	
13	abnormal				abnormal	
14	normal	PA vac			abnormal	
15	—				—	pinhead
16	abnormal	small			abnormal	
17	abnormal	large			abnormal	
18	normal		thick		abnormal	
19	abnormal		thick		abnormal	
20	abnormal	>2 vac	insert		abnormal	
21	normal	>70% acr			abnormal	
22	abnormal	>70% acr			abnormal	
23	abnormal	<40% acr, small			abnormal	
24	abnormal	<40% acr, small			abnormal	
25	abnormal	<40% acr, small			abnormal	
26	abnormal	>70% acr			abnormal	
27	abnormal	<40% acr, >2 vac	irreg		abnormal	
28	normal	>2 vac			abnormal	
29	abnormal	tapered			abnormal	
30	abnormal	tapered			abnormal	
31	abnormal	tapered			abnormal	
32	normal		thick		abnormal	
33	normal		thick		abnormal	
34	abnormal	<40% acr	thick		abnormal	
35	abnormal		thick, bent		abnormal	
36	—				—	pinhead



Morphology assessment of spermatozoa in Plate 4

Sperm	Head shape	Other head comments	Midpiece comments	Principal piece comments	Overall sperm classification	Comments
1	abnormal	flat	thick		abnormal	
2	normal		thick, bent		abnormal	
3	normal		thick		abnormal	
4	normal		thick, bent		abnormal	
5	normal		thick		abnormal	
6	normal		thick		abnormal	
7	abnormal	irreg			abnormal	
8	normal		thick		abnormal	
9	normal		insert, bent		abnormal	
10	normal		thick, bent		abnormal	
11	abnormal	PA vac			abnormal	
12	abnormal				abnormal	
13	abnormal	<40% acr, >2 vac	thick		abnormal	
14	normal		irreg		abnormal	
15	normal		insert		abnormal	
16	normal		thick		abnormal	
17	normal		insert, thick		abnormal	
18	normal		thick, too long		abnormal	
19	normal	<40% acr	insert		abnormal	
20	normal	<40% acr	irreg		abnormal	

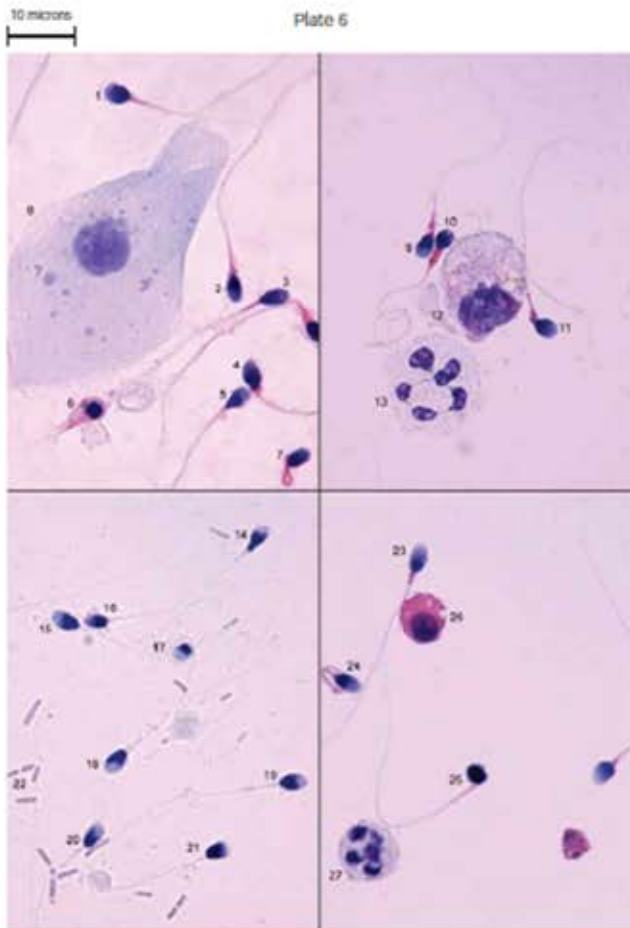
Morphology assessment of spermatozoa in Plate 5



Sperm	Head shape	Other head comments	Midpiece comments	Principal piece comments	Overall sperm classification	Comments
1	abnormal		ERC		abnormal	>one third
2	normal		bent	normal	abnormal	
3	abnormal	>70% acr		looped	abnormal	
4	normal		bent	normal	abnormal	
5	normal		thick	looped	abnormal	
6	abnormal	PA vac		coiled	abnormal	
7	normal				normal	
8	normal			double	abnormal	
9	abnormal			coiled	abnormal	
10	abnormal		bent, insert	coiled	abnormal	
11	normal		thick	bent	abnormal	
12	normal		bent	normal	abnormal	

Micrographs courtesy of C. Brazil

Morphology assessment of spermatozoa in Plate 6

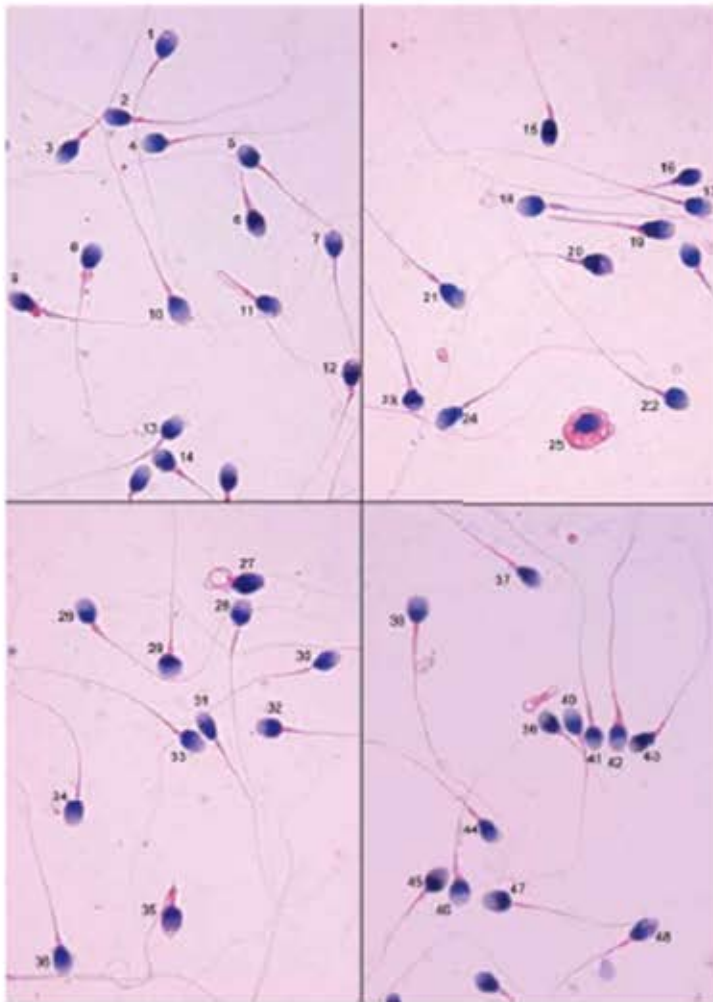


Sperm	Head shape	Other head comments	Midpiece comments	Principal piece comments	Overall sperm classification	Comments
1	normal	<40% acr	thick	normal	abnormal	
2	normal		thick		abnormal	
3	normal				normal	
4	abnormal		thick		abnormal	
5	abnormal	tapered			abnormal	
6					not classifiable	abnormal spermatozoon
7	abnormal		thick	coiled	abnormal	
8						epithelial cell
9	normal		thick, insert		abnormal	
10	abnormal	<40% acr	thick		abnormal	
11	normal		thick		abnormal	
12						degenerating macrophage?
13						polymorph
14	abnormal	pyriform			abnormal	
15	normal				normal	
16	abnormal	<40% acr			abnormal	
17	abnormal	round		not seen	abnormal	free head?
18	abnormal		thick		abnormal	
19	normal				normal	
20	normal				normal	if PP OK
21	abnormal	flat			abnormal	
22						bacilli
23	normal		thick		abnormal	
24	normal		thick	coiled	abnormal	
25	abnormal	amorphous			abnormal	
26						spermatid
27						polymorph

Micrographs courtesy of C. Brazil

10 microns

Plate 7



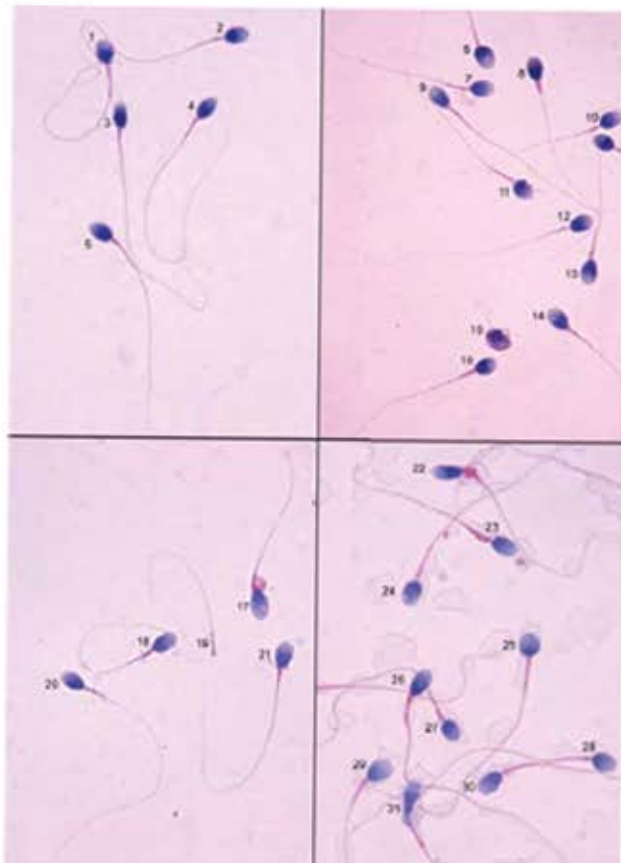
Micrographs courtesy of C. Brazil.

Morphology assessment of spermatozoa in Plate 7

Sperm	Head shape	Other head comments	Midpiece comments	Principal piece comments	Overall sperm classification	Comments
1	normal	2 vac			normal	
2	normal				normal	
3	normal		thick		abnormal	
4	normal				normal	
5	normal				normal	if PP OK
6	normal		thick		abnormal	
7	normal	vac on surface			normal	
8	normal		CD		normal	<one third
9	abnormal		thick, ERC		abnormal	>one third
10	normal				normal	
11	normal	PA vac		looped	abnormal	
12	normal				normal	if PP OK
13	normal	PA vac			abnormal	
14	normal	PA vac			abnormal	
15	abnormal	<40% acr	thick		abnormal	
16	abnormal	<40% acr			abnormal	
17	normal				normal	
18	normal				normal	if PP OK
19	normal		thick	short	abnormal	
20	abnormal		thick		abnormal	
21	normal	>2 vac			abnormal	
22	abnormal	round			abnormal	
23	abnormal	round			abnormal	
24	normal				normal	
25						sperm head in cytoplasm?
26	normal				normal	
27	normal	no acro		coiled	abnormal	
28	normal				normal	
29	abnormal	round			abnormal	
30	normal	PA vac			abnormal	
31	abnormal	tapered, PA vac			abnormal	
32	normal				normal	if PP OK
33	normal				normal	
34	normal				normal	if PP OK
35	abnormal		thick	bent	abnormal	
36	normal				normal	if PP OK
37	normal				normal	if PP OK
38	abnormal	round			abnormal	
39	normal				normal	
40	normal				normal	
41	normal				normal	
42	normal		thick		abnormal	
43	normal	<40% acr			abnormal	
44		out of focus				not assessed
45	abnormal	round			abnormal	
46	abnormal	round			abnormal	
47	normal				normal	
48	normal				normal	if PP OK

10 microns

Plate 8



Micrographs courtesy of C. Brazil.

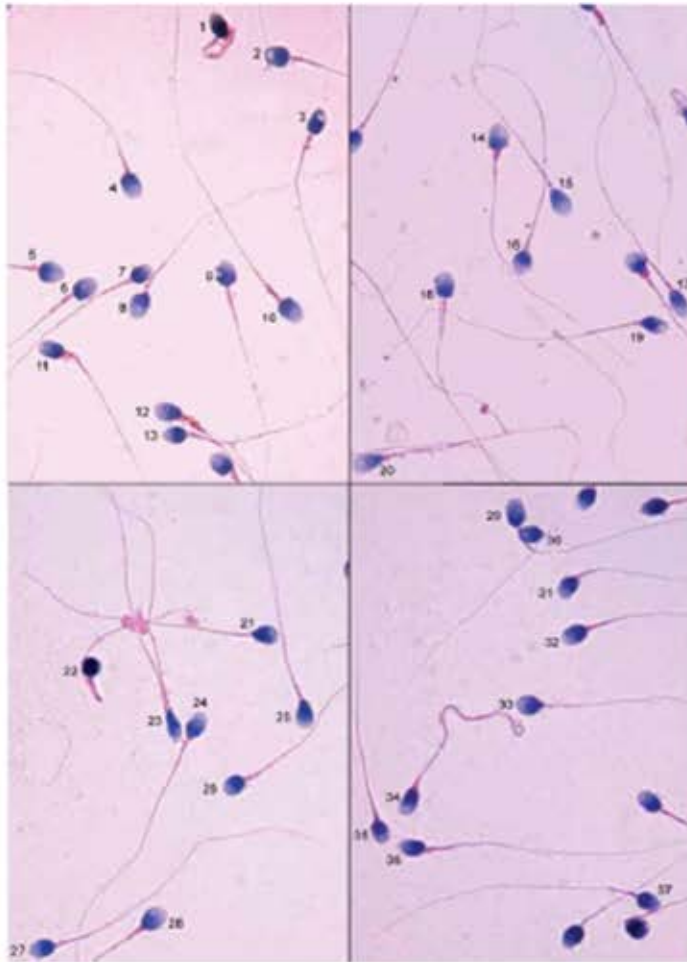
Morphology assessment of spermatozoa in Plate 8

Sperm	Head shape	Other head comments	Midpiece comments	Principal piece comments	Overall sperm classification	Comments
1	normal			normal	normal	
2	normal	>2 vac		normal	abnormal	
3	abnormal	tapered			abnormal	
4	normal			normal	normal	
5	normal				normal	
6	normal				normal	if PP OK
7	normal				normal	if PP OK
8	normal		thick		abnormal	
9	normal				normal	
10	normal				normal	
11	normal	PA vac			abnormal	
12	normal				normal	
13	abnormal				abnormal	
14	normal				normal	if PP OK
15	abnormal	amorphous		defect	abnormal	
16	normal				normal	if PP OK
17	abnormal	>70% acr	thick, ERC		abnormal	>one third
18	normal				normal	
19						pinhead
20	normal				normal	
21	normal	PA vac			abnormal	
22	abnormal	tapered	thick, ERC		abnormal	>one third
23	abnormal	flat	thick		abnormal	
24	normal	>2 vac			abnormal	
25	abnormal	round			abnormal	
26	normal		thick		abnormal	
27	normal		thick		abnormal	
28	normal	>2 vac, >70% acr			abnormal	
29	abnormal				abnormal	
30	normal	>70% acr			abnormal	
31	abnormal	pyriform			abnormal	



10 microns

Plate 9



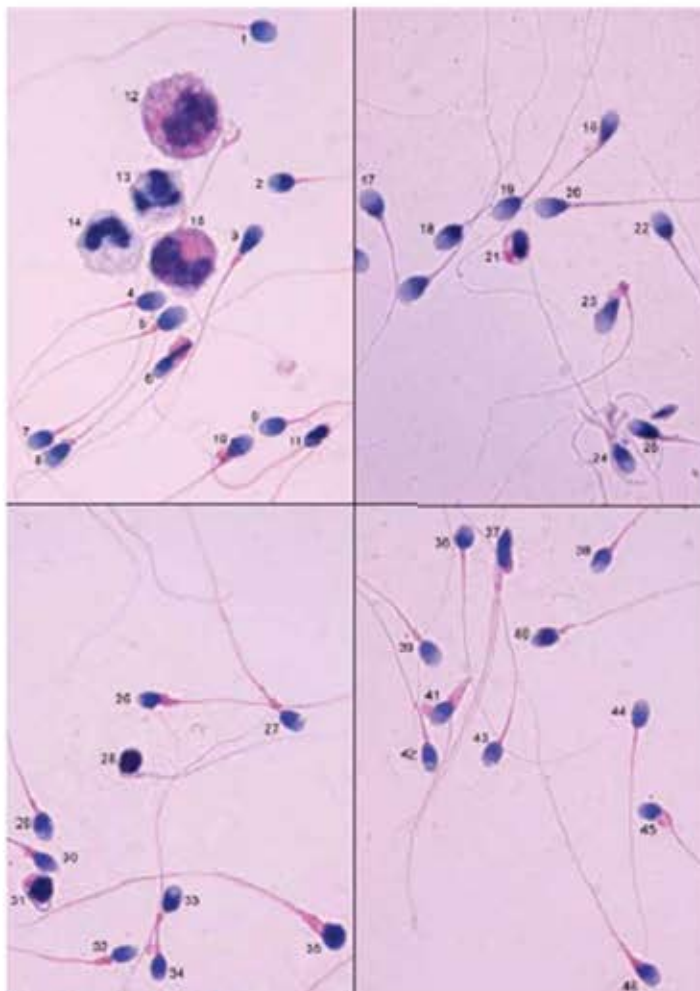
Micrographs courtesy of C. Brazil.

Morphology assessment of spermatozoa in Plate 9

Sperm	Head shape	Other head comments	Midpiece comments	Principal piece comments	Overall sperm classification	Comments
1	abnormal			colloid	abnormal	
2		overlapping				not assessed
3	abnormal	<40% acr			abnormal	
4	normal				normal	if PP OK
5	normal				normal	if PP OK
6	normal	>70% acr	insert		abnormal	
7	normal		insert		abnormal	
8	normal	>70% acr	insert		abnormal	
9	abnormal	PA vac			abnormal	
10	normal	>2 vac	thick		abnormal	
11	abnormal		thick, ERC		abnormal	>one third
12	abnormal		thick, insert, ERC		abnormal	>one third
13	normal				normal	if PP OK
14	abnormal		thick		abnormal	
15	normal			normal	normal	
16	abnormal				abnormal	
17	abnormal	tapered, 3 vac, PA vac			abnormal	
18	normal				normal	
19	abnormal	vac >20%			abnormal	
20	abnormal	tapered			abnormal	
21	normal	PA vac			abnormal	
22	abnormal	amorphous		bent	abnormal	
23	abnormal	tapered		double	abnormal	
24	abnormal	PA vac			abnormal	
25	normal	>2 vac			abnormal	
26	normal				normal	if PP OK
27	normal				normal	
28	normal				normal	if PP OK
29		overlapping				not assessed
30		overlapping				not assessed
31	normal				normal	if PP OK
32	normal				normal	if PP OK
33	normal				normal	if PP OK
34	normal		thick	thick, coiled	abnormal	
35	abnormal	1 side not oval			abnormal	
36	normal	<40% acr			abnormal	
37		overlapping				not assessed

10 microns

Plate 10



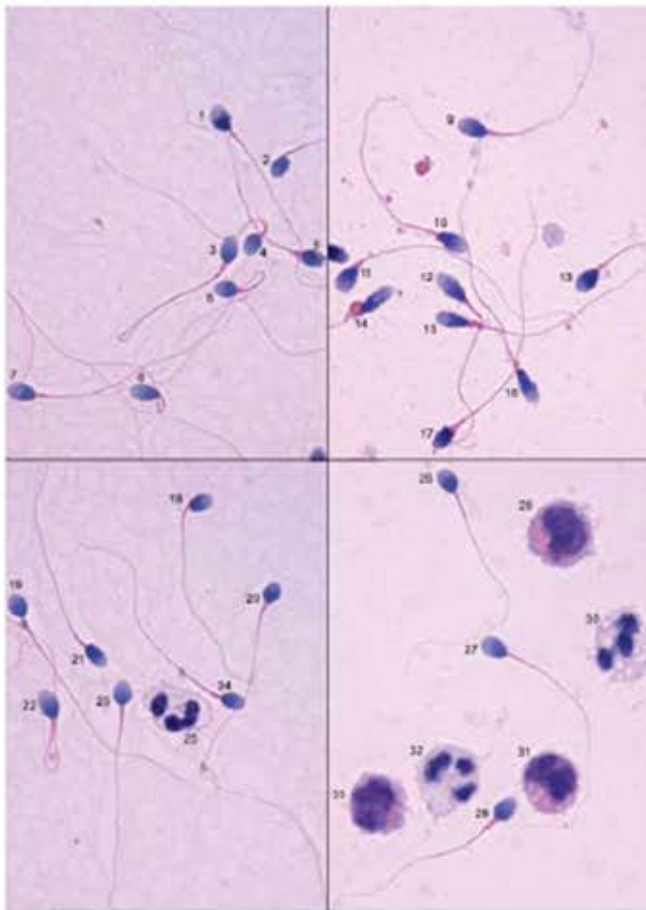
Micrographs courtesy of C. Brazil.

Morphology assessment of spermatozoa in Plate 10

Sperm	Head shape	Other head comments	Midpiece comments	Principal piece comments	Overall sperm classification	Comments
1	normal		insert		abnormal	
2	normal				normal	if PP OK
3	abnormal	pyriform			abnormal	
4	normal				normal	
5	normal		thick		abnormal	
6	abnormal	pyriform	ERC	bent	abnormal	>one third
7	normal				normal	
8	normal				normal	
9	normal	3 vac			abnormal	
10	abnormal	tapered	thick, ERC		abnormal	>one third
11	abnormal	tapered, <40% acr		bent	abnormal	
12						monocytic
13						polymorph
14						polymorph
15						monocytic
16	abnormal	tapered			abnormal	
17	normal				normal	if PP OK
18	normal				normal	
19	normal				normal	
20	normal				normal	if PP OK
21	abnormal	amorphous			abnormal	
22	normal				normal	if PP OK
23	abnormal	tapered	thick	bent	abnormal	
24		overlapping				not assessed
25	abnormal	tapered			abnormal	
26	abnormal	amorphous	thick, ERC		abnormal	>one third
27	normal		thick		abnormal	
28	abnormal	amorphous	thick		abnormal	
29	abnormal	PA vac			abnormal	
30	abnormal		thick		abnormal	
31	abnormal		thick	coiled	abnormal	
32	normal		thick		abnormal	
33		overlapping				not assessed
34		overlapping				not assessed
35	abnormal	amorphous, no acr	thick		abnormal	
36	normal	<40% acr		double	abnormal	
37	abnormal	pyriform	thick		abnormal	
38	normal				normal	if PP OK
39	normal		thick		abnormal	
40	abnormal	<40% acr			abnormal	
41	abnormal		thick	bent	abnormal	
42	normal				normal	if PP OK
43	normal	2 vac, <40% acr			abnormal	
44	normal				normal	
45	abnormal		thick, ERC		abnormal	>one third
46	abnormal		thick		abnormal	

10 microns

Plate 11



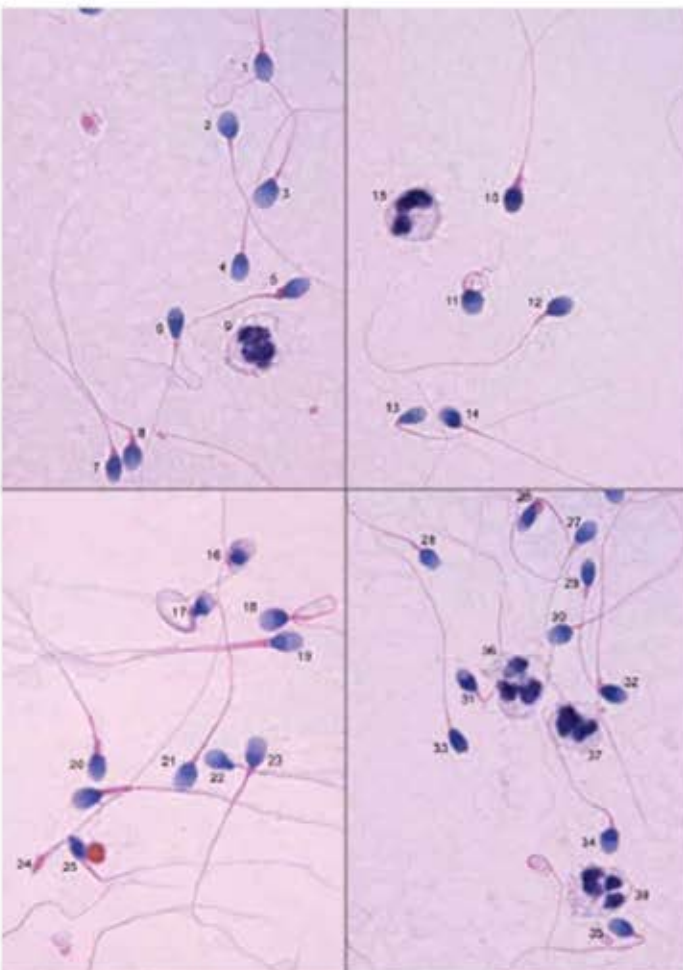
Micrographs courtesy of C. Brazil.

Morphology assessment of spermatozoa in Plate 11

Sperm	Head shape	Other head comments	Midpiece comments	Principal piece comments	Overall sperm classification	Comments
1	abnormal		insert		abnormal	
2	abnormal		insert		abnormal	
3	normal		thick	looped	abnormal	
4	normal				normal	
5	abnormal	>2 vac, <40% acr	thick		abnormal	
6	normal			looped	abnormal	
7	abnormal		insert		abnormal	
8	normal			looped	abnormal	
9	abnormal	>70% act, tapered			abnormal	
10	abnormal	tapered			abnormal	
11	normal		thick		abnormal	
12	abnormal	tapered			abnormal	
13	normal	<40% acr	thick		abnormal	
14	abnormal	tapered	thick, ERC		abnormal	>one third
15	abnormal	tapered	thick		abnormal	
16	abnormal	tapered			abnormal	
17	abnormal	amorphous	thick		abnormal	
18	normal				normal	
19	normal				abnormal	
20	abnormal				abnormal	
21	abnormal				abnormal	
22	normal	>70% acr		looped	abnormal	
23	normal				normal	
24	normal				normal	
25						polymorph
26	normal				normal	
27	normal				normal	
28	normal	>70% acr			abnormal	
29						monocyte
30						polymorph
31						monocyte
32						polymorph
33						monocyte

10 microns

Plate 12



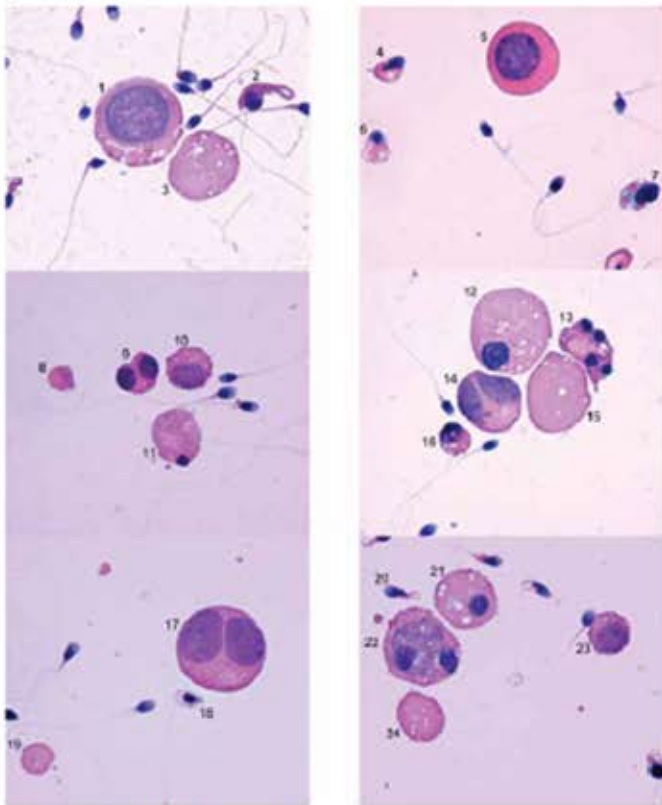
Micrographs courtesy of C. Brazil.

Morphology assessment of spermatozoa in Plate 12

Sperm	Head shape	Other head comments	Midpiece comments	Principal piece comments	Overall sperm classification	Comments
1	normal	>70% acr			abnormal	
2	abnormal				abnormal	
3	abnormal	>70% acr			abnormal	
4	normal				normal	if PP OK
5	abnormal		thick		abnormal	
6	abnormal	tapered			abnormal	
7		not in focus	thick			not assessed
8	abnormal		thick, bent		abnormal	
9						degenerating leukocyte
10	abnormal		thick		abnormal	
11	abnormal	round		coiled	abnormal	
12	normal				normal	
13	abnormal	tapered	bent		abnormal	
14	abnormal		insert		abnormal	
15						polymorph
16	abnormal	amorphous			abnormal	
17	abnormal			coiled	abnormal	
18	abnormal		thick	coiled	abnormal	
19	normal			double	abnormal	
20	abnormal		thick		abnormal	
21		overlapping				not assessed
22	abnormal	pyriform			abnormal	
23	normal				normal	
24	abnormal				abnormal	pinhead
25	abnormal	amorphous		bent	abnormal	
26	abnormal	amorphous	thick, bent		abnormal	
27	normal		thick		abnormal	
28	normal				normal	if PP OK
29	abnormal	tapered			abnormal	
30	abnormal	round			abnormal	
31	normal		bent	overlap		not assessed
32	normal		thick, bent		abnormal	
33	abnormal				abnormal	
34	abnormal				abnormal	
35	normal		bent		abnormal	
36						polymorph
37						polymorph
38						polymorph

15 microns

Plate 13



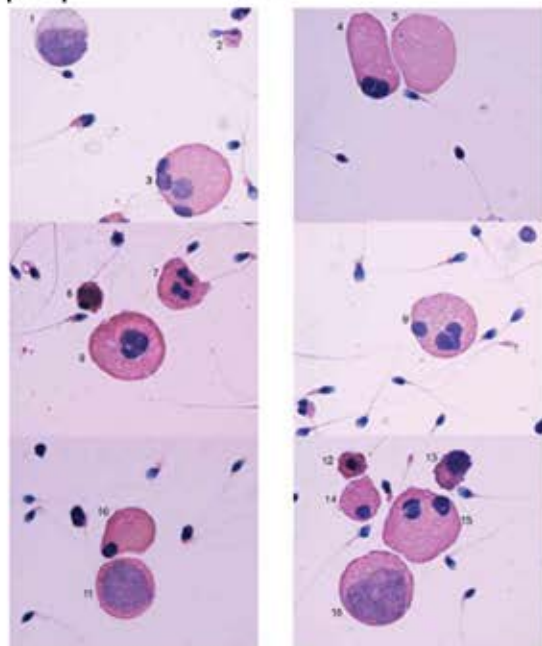
Micrographs courtesy of C. Brazil

Assessment of cells in Plate 13

Cell	Cell type
1	macrophage
2	abnormal spermatozoon
3	cytoplasm
4	abnormal spermatozoon
5	spermatocyte
6	abnormal spermatozoon
7	abnormal spermatozoon? Loose head on cytoplasm?
8	cytoplasm
9	dividing spermatid
10	spermatocyte
11	degenerating spermatid
12	spermatid
13	degenerating spermatid
14	dividing spermatocyte
15	cytoplasm
16	degenerating spermatid
17	dividing spermatocyte
18	abnormal spermatozoon
19	cytoplasm
20	abnormal spermatozoon
21	spermatid
22	phagocytosing macrophage
23	spermatocyte
24	cytoplasm

15 microns

Plate 14



Micrographs courtesy of C. Brazil

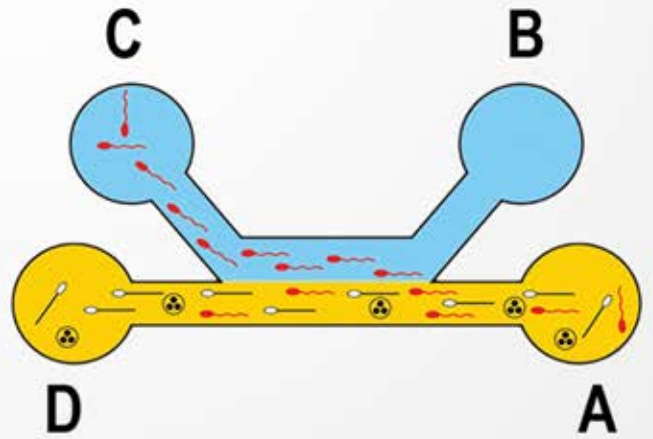
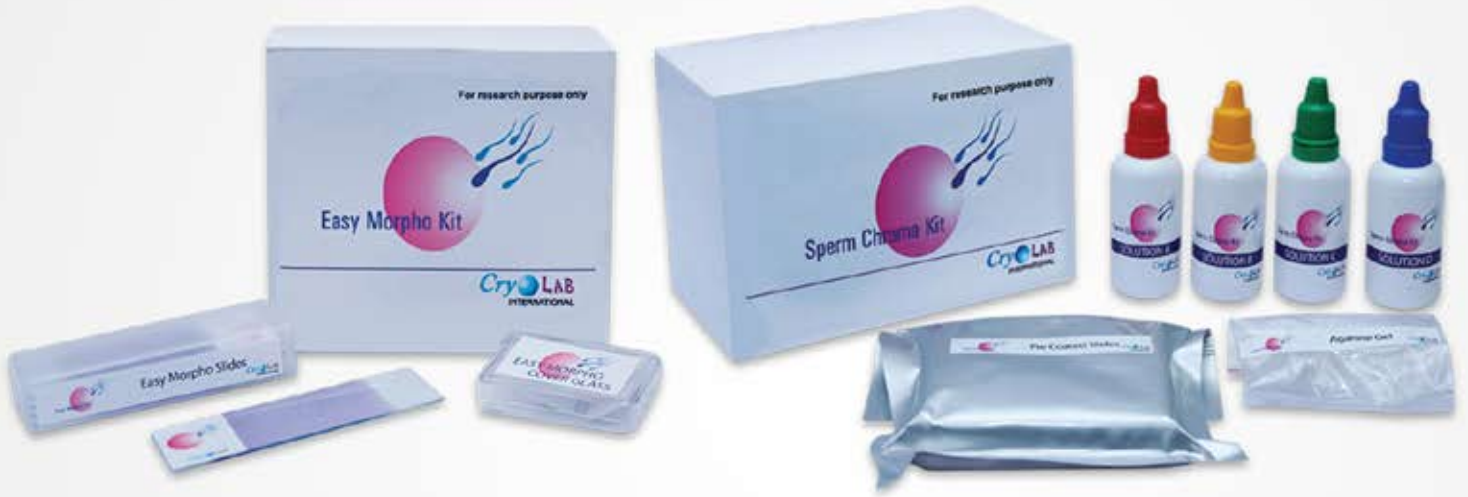
Assessment of cells in Plate 14

Cell	Cell type
1	macrophage
2	abnormal spermatozoon
3	(dividing) spermatid
4	(dividing) spermatid
5	cytoplasm
6	not classifiable
7	degenerating spermatid
8	degenerating spermatid?
9	degenerating spermatid
10	degenerating spermatid
11	macrophage
12	degenerating spermatid
13	degenerating spermatid
14	degenerating spermatid
15	degenerating spermatid
16	macrophage



# SAR HEALTHLINE

GATEWAY TO INDIAN IVF



### We Serve You Near

- |           |           |             |         |           |             |         |
|-----------|-----------|-------------|---------|-----------|-------------|---------|
| Ahmedabad | Bangalore | Bhubaneswar | Chennai | Cochin    | Coimbatore  | Calicut |
| Guwahati  | Hyderabad | Indore      | Jaipur  | Jalandar  | Kolkata     | Lucknow |
| Madurai   | Mumbai    | Nanganallur | Nagpur  | New Delhi | Navi Mumbai | Patna   |
| Pune      |           |             |         |           |             |         |